

## What next?

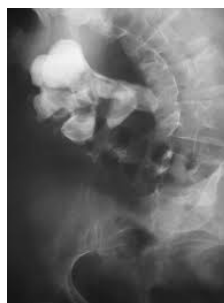- You may spend at least 3-5 nights in hospital
- You may have a catheter for that time.
- You may have a nephrostomy tube in the affected kidney for at least 3 days
- You may have a check CT scan the following day to confirm stone clearance.
- After removal of the nephrostomy tube, you may experience urine leak from the wound site for a few days.
- Your catheter will be removed a day after.
- You may be discharged as soon as your pain has stabilised and you can function independently.
- Allow for a few days for stabilization of symptoms.
- A ward prescription will be issued on your discharge, for your own collection at any pharmacy
- A follow-up appointment will be scheduled for 6 weeks. Stone analysis results will then be discussed in order to formulate a plan to prevent recurrences
- Don't hesitate to ask Jo if you have any queries
- **DON'T SUFFER IN SILENCE, OR YOU WILL SUFFER ALONE!**

## Types of Stones:

- Calcium Oxalate
- Uric Acid
- Calcium Phosphate
- Struvite (Infection stones)
- Cystine

## Possible complications:

- Hemorrhaging requiring embolization of bleeder, and blood transfusion
- Possible nephrectomy in 1-5% of patients
- Very rarely death has also resulted less than 0.5%
- Residual stone fragments
- Missed stone fragments in the ureter causing obstruction and pain



### Jo Schoeman

FRACS, FCS (Urol) SA, MBChB

Pelvic Medicine Centre  
St Andrews War Memorial Hospital  
Wickham Terrace  
Springhill, Brisbane QLD 4000

Ph: 07) 3831-9049

Fax: 07) 3834-4471

E-mail: [admin@brisbane-urology.com.au](mailto:admin@brisbane-urology.com.au)

Emerg: 0403 044 072

# Urologist



**Dr Jo Schoeman**  
Specialist Urologist

## PATIENT INFORMATION BROCHURE

*PERCTANEOUS  
NEPHRO-LITHOTOMY  
(PCNL)*

---

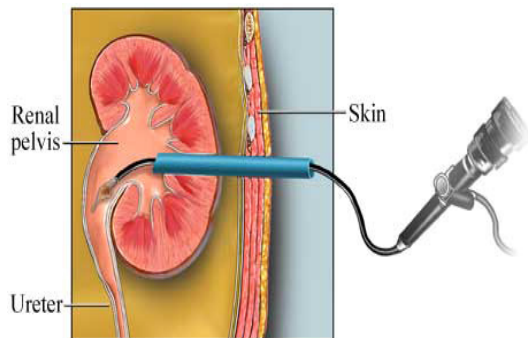
Patient well-being is my first priority!

## Perctaneous Nephro-lithotomy (PCNL)

Endoscopic surgery with trans-cutaneous access through lower lumbar area. Indicated for stones larger than 1,5cm, situated in the kidney

### Why is it done?

- **Renal stones** usually larger than 1,5cm obstructing/ non-obstructing the renal pelvis
- Staghorn calculus
- Quicker removal, more effective removal
- Higher stone free rates in less time
- 90% of patients are stone free after this procedure
- You may present with excruciating pain on the affected side if the stone is lodged at the pelvi-uretric junction. (This pain may be worse than child-birth)
- Non-obstructing renal stones may not cause any symptoms, yet need to be treated to prevent enlargement and future renal failure and sepsis
- **Any fevers or a single kidney is deemed an emergency! This requires urgent stenting or a nephrostomy prior**

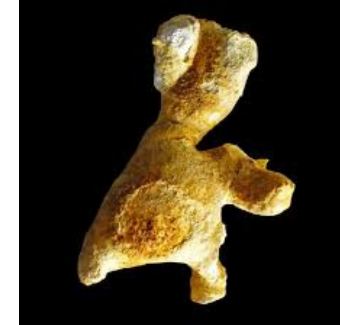

### How is it done?

- Patients will receive a general anaesthesia.
- Prophylactic antibiotics is given.
- The correct kidney is identified and marked while you are awake
- A cystoscopy with retrograde pyelogram will be done with placement of ureteric occlusion catheter to enable filling of the renal collecting system, aiding in the initial percutaneous access to the kidney.
- You will then be placed prone (face down) on the operating table with good support.
- Using radiological imaging a needle will be placed into the desired calyx (collecting system) of the kidney
- A guidewire will be placed and the tract dilated to allow the access of the nephroscope
- Either the lithoclast or laser will be used to fragment the stone.
- All fragments will be attempted to be cleared. Small 1-2 mm fragments may be left as "Clinically Insignificant Fragments CISF" and will pass spontaneously
- A nephrostomy tube (drainage tube) is left post-operatively for a few days until bleeding settles.
- A CT scan will be done the following day to determine whether all the stones have been removed
- In the event of residual stone being present, the recommendation may be made to keep the nephrostomy tube in longer until an appropriate time on a theatre list can be accessed to remove the remaining calculus
- Should you be stone free, your nephrostomy tube will be removed followed by your indwelling catheter a day later
- Urine leakage from the puncture site may persist for a few days until the wound heals over

### Treatment Options

1. Single Entry
2. Multiple Entry, Staged procedure for stag horn calculi or multiple stones
3. Use of a combined flexible nephroscopy with laser in those difficult corners



### Options for Residual Fragments

1. Keep nephrostomy until appropriate date to re-enter the same tract and remove the rest of the stone
2. Remove the tube and plan for ESWL (Extra-Corporeal Shock Wave Lithotripsy)
3. If radio-luscent: possible dissolution therapy

